



MEDFORD

Multi Speciality Hospital

From Cure To Care, Your Bridge To Healthcare



| | | | |
|---------|---------------------------|-----------------|----------------|
| NAME | : MAST. MOHD HAMZA SHAIKH | AGE/SEX | : 16 DAYS/MALE |
| UHID NO | : MF-200925-05306 | REGISTRATION ON | : 20.09.2025 |
| REF BY | : DR. POOJA SUTAR | REPORTED ON | : 20.09.2025 |

ULTRA SOUND ABDOMEN & PELVIS

LIVER: Normal in size (7.7 cm) and shows homogenous echo texture. No evidence of focal or diffuse space occupying lesion. No Evidence of intra hepatic biliary radicals dilatation. Portal vein at porta shows normal hepatopetal flow.

GALL BLADDER: Is distended and appears normal. **Mild gall bladder wall edema measuring 4-5 mm noted.** No e/o GB calculi or sludge noted. No e/o pericholecystic fluid collection. CBD appears normal.

SPLEEN: Normal in size (5.6 cm) and shows homogenous echo texture

PANCREAS: Normal in size and shows homogenous echo texture

Bilateral renal pelvis appears mildly dilated measures 8-9 mm.

RIGHT KIDNEY: Measures: 4.8 x 2.0 cm. It appears normal in size, shape, position and echo texture. Corticomedullary junction is well maintained. Perinephric areas appear normal.

LEFT KIDNEY: Measures: 4.8 x 2.3 cm. It appears normal in size, shape, position and echo texture. Corticomedullary junction is well maintained. Perinephric areas appear normal.

URINARY BLADDER: Well filled up and appears normal. No evidence of calculus / Diverticulum.


PROSTATE: Normal for age.



No significant lymphadenopathy or free fluid is seen in abdomen.

IMPRESSION:

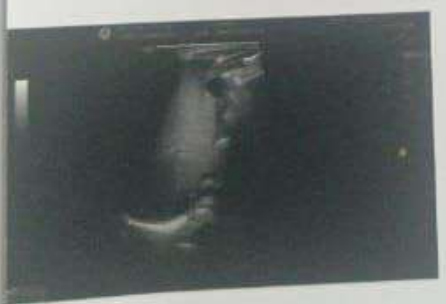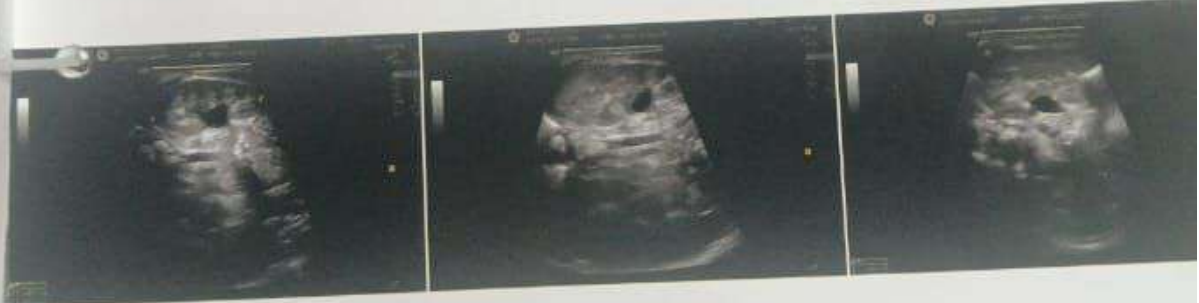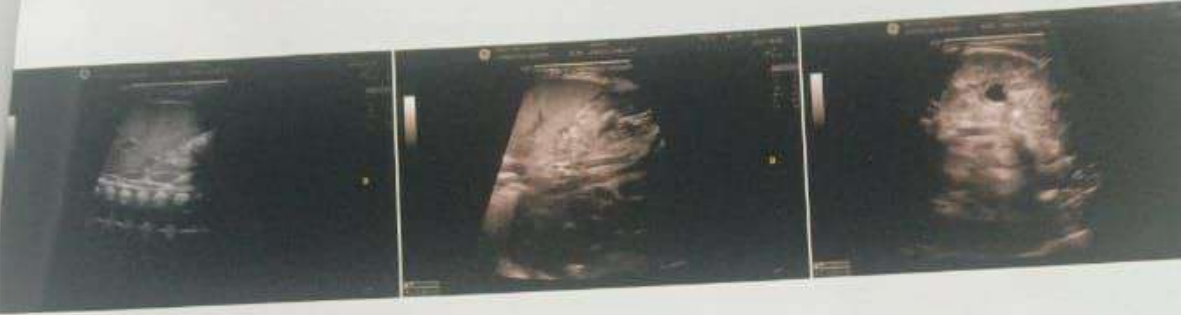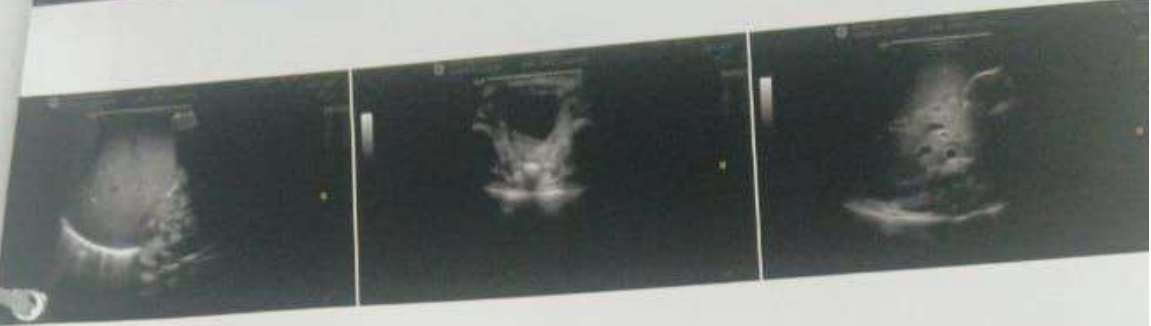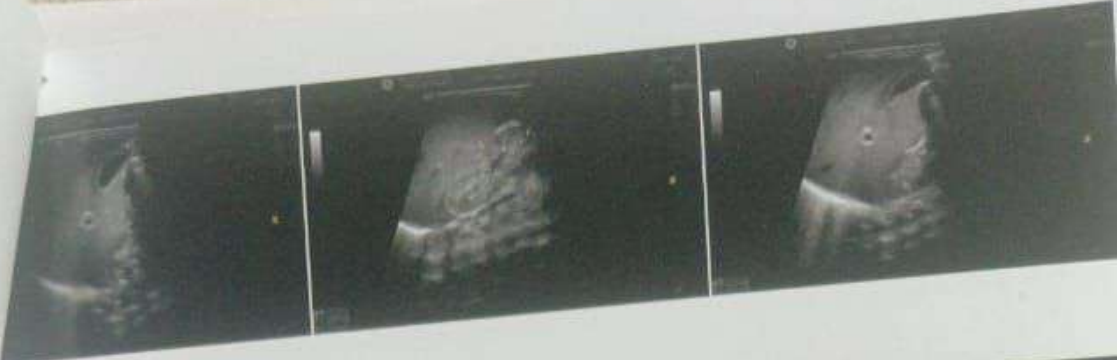- Mild gall bladder wall edema.
- Bilateral renal pelvis mildly dilated.

Recommended clinical / lab correlation


DR. MOHAMMAD SOHAIL
(MBBS) (DMRI)
CONSULTANT RADIOLOGIST

Mob.: 9769 0000 91 / 9769 0000 92 / 9769 0000 93 Follow Us On  

1st Floor, Noori Blue Bells, Nr. Bypass Y-Junction, Kausa-Mumbra, Thane - 400 012. www.medfordhealthcare.com





Insight For A Healthier Tomorrow

MEDFORD

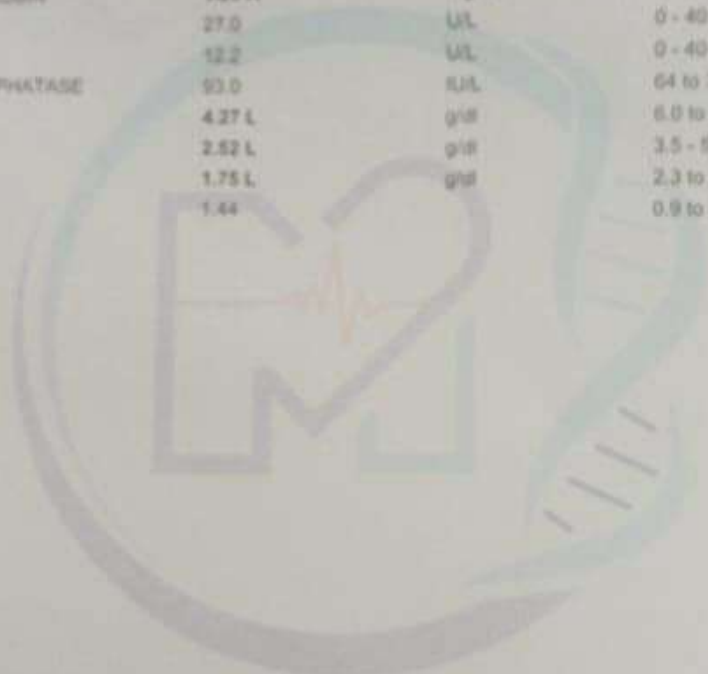DIAGNOSTIC CENTRE

Powered by
MedBliss


Patient Name : **BABA MOHAMMED HAMZA SHAIKH** Patient ID : 20250920-0365-3386
Age/Sex : 16 Days / Male Sample Collected on : 20/09/2025, 06:10 PM
Ref Doctor : **POOJA SUTAR** Registration On : 20/09/2025, 06:20 PM
Client Name : **MEDFORD HOSPITAL** Reported On : 20/09/2025, 07:48 PM

LIVER FUNCTION TEST

| PARAMETER | VALUE | UNIT | RANGE |
|----------------------|--------|-------|------------|
| TOTAL BILIRUBIN | 1.95 H | mg/dL | 0 - 1.2 |
| DIRECT BILIRUBIN | 0.72 H | mg/dL | 0 - 0.5 |
| INDIRECT BILIRUBIN | 1.23 H | mg/dL | 0 - 0.7 |
| SGOT (AST) | 27.0 | U/L | 0 - 40 |
| SGPT (ALT) | 12.2 | U/L | 0 - 40 |
| ALKALINE PHOSPHATASE | 93.0 | U/L | 64 to 306 |
| S. PROTEIN | 4.27 L | g/dl | 6.0 to 8.3 |
| S. ALBUMIN | 2.52 L | g/dl | 3.5 - 5.0 |
| S. GLOBULIN | 1.75 L | g/dl | 2.3 to 3.6 |
| A/G RATIO | 1.44 | | 0.9 to 2.3 |



Printed by arsh


DR. PRIYANKA JAIN
(CONSULTING PATHOLOGIST)
REG. NO. 2017020327

Shop No. 5 & 6, Noori Blue Bells, Below Medford Hospital,
Tr. Bypass Y Junction, Kausa, Mumbra - 400 612

 +91 97690 00093



Insight For A Healthier Tomorrow

MEDFORD

DIAGNOSTIC CENTRE

Powered by
MedBios


Patient Name: **BABA MOHAMMED HAMZA SHAIKH**
Age/Sex: **18 Days / Male**
Ref Doctor: **POOJA SUTAR**
Clinic Name: **MEDFORD HOSPITAL**

Patient ID: **20250920-0365-3386**
Sample Collected on: **20/09/2025, 06:10 PM**
Registration On: **20/09/2025, 06:20 PM**
Reported On: **20/09/2025, 07:48 PM**

RENAL FUNCTION TEST

| PARAMETER | VALUE | UNIT | RANGE |
|---------------------|---------|-------|------------|
| BLOOD UREA | 30.1 | mg/dL | 10 - 30 |
| BLOOD UREA NITROGEN | 14.07 | mg/dL | 0.0 - 23.0 |
| S. CREATININE | 0.52 L | mg/dL | 0.7 to 1.4 |
| S. SODIUM | 129.7 L | mEq/L | 135 - 155 |
| S. POTASSIUM | 5.50 | mEq/L | 3.5 - 5.5 |
| S. POTASSIUM | 98.9 | mEq/L | 95 - 109 |
| S. CHLORIDE | 3.30 L | mg/dL | 3.5 - 7.2 |
| S. URIC ACID | 8.30 L | mg/dL | 8.4 - 10.4 |
| S. CALCIUM | 5.65 H | mg/dL | 2.0 - 4.5 |
| S. PHOSPHORUS | 4.27 L | g/dl | 0.0 to 8.3 |
| S. PROTEIN | 2.52 L | g/dl | 3.5 to 5.3 |
| S. ALBUMIN | 1.75 L | g/dl | 2.3 to 3.6 |
| S. GLOBULIN | 1.44 | | 0.9 - 2.3 |
| AG RATIO | | | |

Printed by arsh


DR. PRIYANKA JAIN
(CONSULTING PATHOLOGIST)
REG. NO. 2017020327

Shop No. 5 & 6, Noori Blue Bells, Below Medford Hospital,
Nr. Bypass Y Junction, Kausa, Mumbra - 400 612

+91 97690 00093



Insight For A Healthier Tomorrow

MEDFORD

DIAGNOSTIC CENTRE

Powered by
MedBliss

Patient Name : **BABA MOHAMMED HAMZA SHAIKH** Patient ID : 20250920-0365-3386
Age/Sex : 16 Days / Male Sample Collected on : 20/09/2025, 06:10 PM
Ref Doctor : POOJA SUTAR Registration On : 20/09/2025, 06:20 PM
Client Name : MEDFORD HOSPITAL Reported On : 20/09/2025, 07:48 PM

VENOUS BLOOD GAS (VBG)

| PARAMETER | VALUE | UNIT | RANGE |
|-----------------------------------|--------|--------|------------|
| PH | 7.464 | | 7.2 to 7.6 |
| PCO2 | 47.1 | mmHg | 30 to 50 |
| PO2 | 94.8 | mmHg | 80 - 100 |
| BASE EXCESS (BE) | 9.6 | mmol/L | |
| TOTAL CO2 (TCO2) | 34.5 | mmol/L | |
| ACTUAL BICARBONATE (HCO3) | 33.4 H | mmol/L | 22 - 26 |
| HEMOGLOBIN / OXYGEN STATUS | | | |
| TOTAL HEMOGLOBIN (THB) | 10.3 L | | 12 to 17 |
| HB OXYGEN SATURATION (SO2) | 97.4 | % | 90 to 100 |

END OF REPORT

DR. PRIYANKA JAIN
(CONSULTING PATHOLOGIST)
REG. NO. 2017020327

Printed by arsh



Shop No. 5 & 6, Noori Blue Bells, Below Medford Hospital,
Nr. Bypass Y Junction, Kausa, Mumbra - 400 612



+91 97690 00093



Insight For A Healthier Tomorrow

MEDFORD

DIAGNOSTIC CENTRE

Powered by
MedBliss


Patient Name : BABA MOHAMMED HAMZA SHAIKH Patient ID : 20250920-0365-3376
Age/Sex : 16 Days / Male Sample Collected on : 20/09/2025, 01:15 PM
Ref Doctor : POOJA SUTAR Registration On : 20/09/2025, 01:20 PM
Client Name : MEDFORD HOSPITAL Reported On : 20/09/2025, 02:02 PM

URINE ROUTINE EXAMINATION

| PARAMETER | VALUE | UNIT | RANGE |
|--------------------------------|------------------------|------|---------------|
| Physical Examination | | | |
| VOLUME | 05 ML | ml | - |
| COLOUR | Pale Yellow | | Pale Yellow |
| APPEARANCE | Slightly Hazy | | Clear |
| DEPOSIT | Present | | Absent |
| Chemical Examination | | | |
| REACTION (PH) | Acidic (6.0) | | Acidic |
| SPECIFIC GRAVITY | 1.025 | | 1.003 - 1.035 |
| PROTEIN (ALBUMIN) | Present (+) | | Absent |
| OCCULT BLOOD | Negative | | Negative |
| SUGAR | Absent | | Absent |
| KETONES | Absent | | Absent |
| BILE SALT & PIGMENT | Absent | | Absent |
| UROBILINOGEN | Normal | | Normal |
| Microscopic Examination | | | |
| RED BLOOD CELLS | Occasional | | Absent |
| PUS CELLS | 8-10 /HPF H | | 0 - 5 |
| EPITHELIAL CELLS | 4-5 /HPF | | 0 - 4 |
| CASTS | Granular Cast- Present | | Absent |
| CRYSTALS | Absent | | Absent |
| BACTERIA | Absent | | Absent |
| YEAST CELLS | Absent | | Absent |
| ANY OTHER FINDINGS | Absent | | Absent |

----- END OF REPORT -----

Printed by iram


DR. PRIYANKA JAIN
(CONSULTING PATHOLOGIST)
REG. NO. 2017020327



Shop No. 5 & 6, Noori Blue Bells, Below Medford Hospital,
Nr. Bypass Y Junction, Kausa, Mumbra - 400 612



+91 97690 00093



Insight For A Healthier Tomorrow

MEDFORD

DIAGNOSTIC CENTRE

Powered by
MedBliss

Patient Name : BABA MOHD HAMZA SHAIKH
Age/Sex : 20 Days / Male
Ref Doctor : POOJA SUTAR
Client Name : MEDFORD HOSPITAL

Patient ID : 20250920-0363-3524
Sample Collected on : 24/09/2025, 08:36 AM
Registration On : 24/09/2025, 08:49 AM
Reported On : 24/09/2025, 09:07 AM

C REACTIVE PROTEIN (CRP) - QUANTITATIVE

| PARAMETER | VALUE | UNIT | RANGE |
|--------------------|---------|------|-------|
| CRP - QUANTITATIVE | 125.0 H | mg/L | 0 - 6 |

----- END OF REPORT -----



DR. PRIYANKA JAIN
(CONSULTING PATHOLOGIST)
REG.No. 2017020327

Printed by failb

Shop No. 5 & 6, Noori Blue Bells, Below Medford Hospital,
Nr. Bypass Y Junction, Kausa, Mumbra - 400 612

+91 97690 00093



MEDFORD

Multi Speciality Hospital

From Cure To Care, Your Bridge To Healthcare



| | | | |
|--------|---------------------------|--------------|--------------|
| NAME | : MAST, MOHD HAMZA SHAIKH | AGE/SEX | : NB /MALE |
| UHID | : MF-200925-05306 | REGISTRATION | : 22.09.2025 |
| NO | | ON | |
| REF BY | : DR. POOJA SUTAR | REPORTED ON | : 22.09.2025 |

USG LOCAL PART (Left Shoulder & Elbow)

FINDINGS AND IMPRESSION:

- Diffuse inflammatory changes noted around left humerus with small clefts of fluid around proximal humerus.
- Minimal joint effusion seen of left shoulder.
- No obvious effusion or collection seen of elbow joint.

Recommended clinical / lab correlation.

DR. SALMAN K
MBBS, DNB, EDiR, DICRI
CONSULTANT RADIOLOGIST

Mob.: 9769 0000 91 / 9769 0000 92 / 9769 0000 93 Follow Us On  

1st Floor, Noori Blue Bells, Nr. Bypass Y-Junction, Kausa-Mumbra, Thane - 400 612. www.medfordhealthcare.com



MEDFORD

Multi Speciality Hospital

From Cure To Care, Your Bridge To Healthcare



| | | | |
|---------|---------------------------|-----------------|--------------|
| NAME | : MAST. MOHD HAMZA SHAIKH | AGE/SEX | : NB /MALE |
| UHID NO | : MF-200925-05306 | REGISTRATION NO | : 22.09.2025 |
| REF BY | : DR. POOJA SUTAR | REPORTED ON | : 22.09.2025 |

USG LOCAL PART (Both Hip)

FINDINGS AND IMPRESSION:

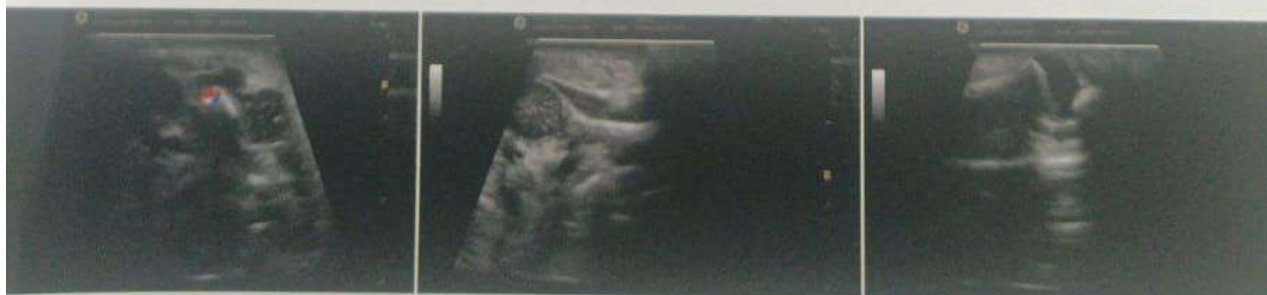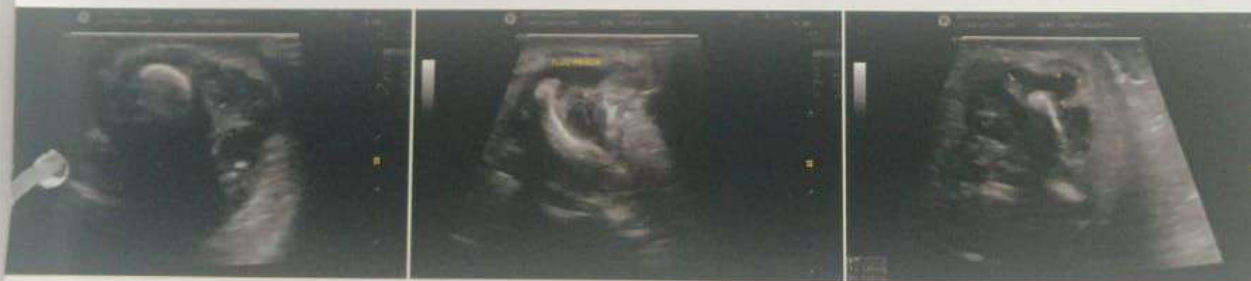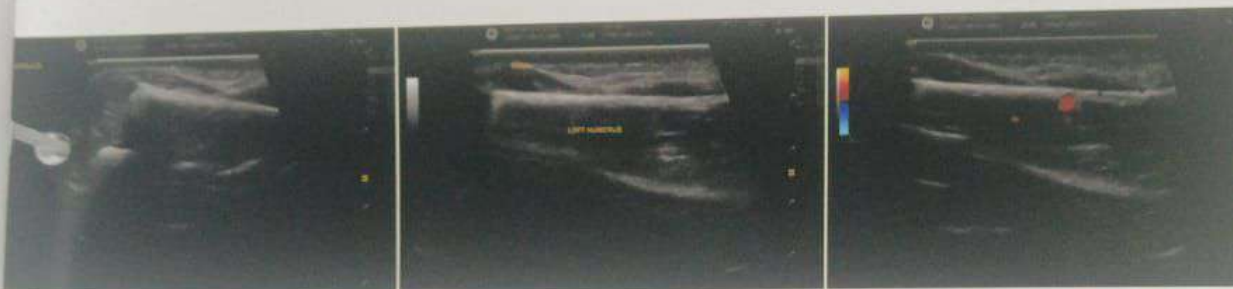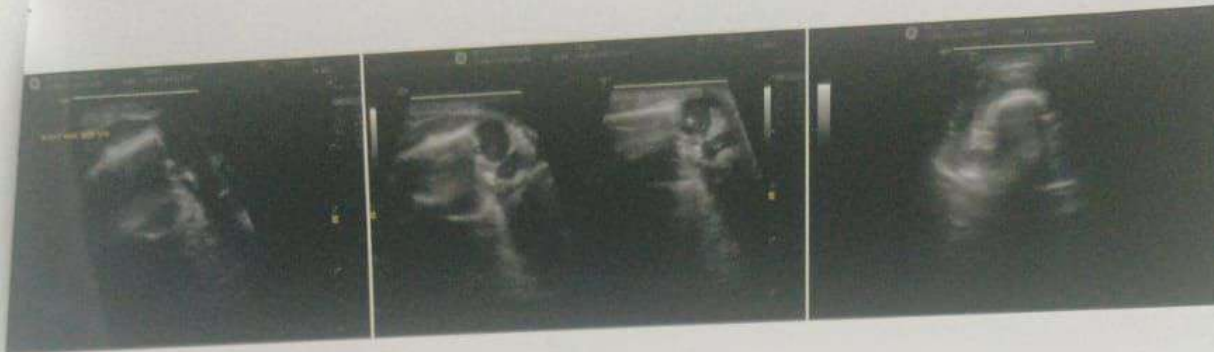- No obvious hip joint effusion or collection.
- Mild effusion seen in suprapatellar recess of right knee.
- Diffuse subcutaneous edema seen along abdominal wall & thigh on either side.

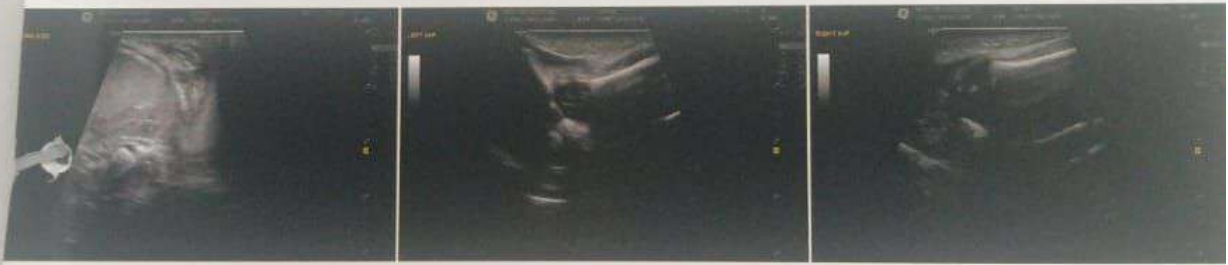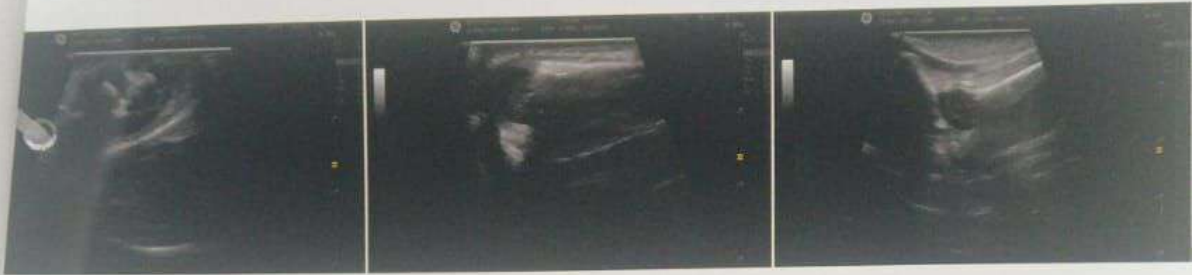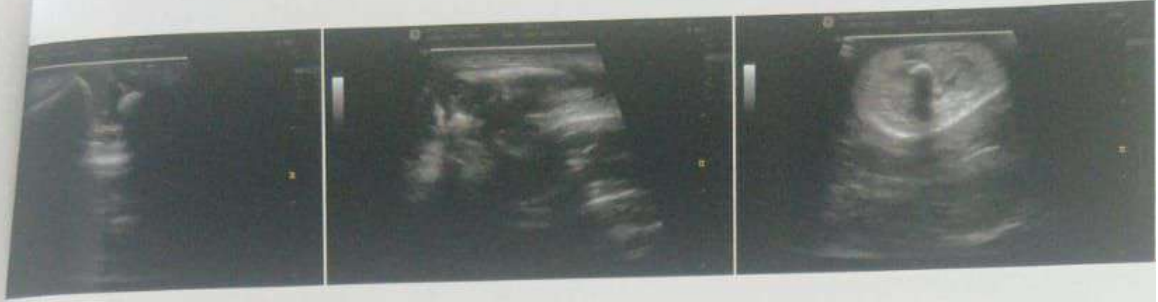Recommended clinical / lab correlation.

DR. SALMAN K
MBBS, DNB, EDiR, DICRI
CONSULTANT RADIOLOGIST

Mob.: 9769 0000 91 / 9769 0000 92 / 9769 0000 93 Follow Us On  

1st Floor, Noori Blue Bells, Nr. Bypass Y-Junction, Kausa-Mumbra, Thane - 400 612. www.medfordhealthcare.com







Insight For A Healthier Tomorrow

MEDFORD

DIAGNOSTIC CENTRE

Powered by
MedBliss

| | | | |
|----------------|-----------------|----------------|---------------------|
| Patient Name : | BABA HAMZA | Age / Gender : | 18DAYS / M |
| Patient ID : | TR-8413360 | Date & Time : | 22-09-2025 09:01 PM |
| Refd By : | DR. POOJA SUTAR | Modality : | X-ray |

X-ray - BOTH FOREARM AP/LAT

FINDINGS:

Bony surfaces and articular margins of bones of hand are normal.
No evidence of fracture, bone destruction or cystic areas is seen.
Visualized wrist joint and carpometacarpal joint space is normal.
Bones shows normal architecture.
No soft tissue calcification is seen.

IMPRESSION:

- No evidence of fracture.
- No significant bony abnormality is noted in Both Hand Study.

Please correlate clinically.

Dr Bikramjit Sahu
MBBS,DNB
Consultant Radiologist
NBE/CONV/2014/18/5613

Disclaimer: Disclaimer: This is an online interpretation of the images provided. If there is any clinical discrepancy, this investigation may be repeated or assessed by other tests. Patient's identification in online reporting is not established, so in no way this report can be utilized for any medicolegal purpose

MEDICAL LABORATORY REPORT
MEDICAL LABORATORY REPORT



This is a Technical Analysis, data should be judged & interpreted by registered medical practitioner.

| | | | |
|---------------------|----------------------------|---------------|-----------------------|
| Lab No. : | HA2912 | Reg. Date : | 20-Sep-2025 3:51 pm |
| Patient's Name : | BABA MOHAMMED HAMZA SHAIKH | Sample Date : | 20-Sep-2025 3:46 pm |
| Referred By : | DR POOJA-SUTAR | Report Date : | 22-Sep-2025 10:12 am |
| Location : | | Print Date : | 22-Sep-2025 / 3:00 pm |
| Collection Center : | MEDFORD DIAGNOSTIC CENTRE | Sex / Age : | Male / 16 DAYS Years |

BLOOD CULTURE AND SENSITIVITY TEST

BLOOD CULTURE

| | |
|--------------------------------|---|
| REPORT | PRELIMINARY REPORT |
| SPECIMEN | Blood received in Pediatric Blood culture broth on 20/09/2025 |
| METHOD | Blood processed on BacT/ALERT 3D from bioMerieux |
| MACROSCOPIC EXAMINATION | |
| RESULT | Signs of Microbial growth. |
| SMEAR EXAMINATION | |
| Gram's Stain | Gram negative bacilli detected on smear examination. |
| ORGANISMS ISOLATED | |
| Result | Gram negative organism isolated on culture. |
| Note | Identification and Antibiotic susceptibility testing results awaited. |

----- End of Report -----

Clinical Correlation To Be Done. All Testing Done At Quallife Diagnostic

Printed by DIPTI

Page 1 of 1



Checked by _____

📍 Balaj Arcade, 1st Floor, 544/A, Netaji Subhash Road,
Near Dhulewadi Hospital, Mulde (W), Mumbai-400 080.
☎ +91 22 2591 6464 📠 +91 90194 63005 📠 +91 90294 44028
📧 : quallifediagnostic@gmail.com 🌐 : www.quallifediagnostic.com
Timing : Mon. - Sat. 8 am to 9 pm | Sun - 8 am to 12 noon

J#
Dr. Roopa Viswanathan
MD (Micro) **Dr. Roopa Viswanathan**
Chief Microbiologist, Founder and
Senior Microbiologist, Founder and
Reg. No. 082811
Thanks for your reference



Insight For A Healthier Tomorrow

MEDFORD

DIAGNOSTIC CENTRE

Powered by
MedBliss

| | | | |
|----------------|------------------------------|----------------|---------------------|
| Patient Name : | BABA MOHD HAMZA AFZAL SHAIKH | Age / Gender : | 20 DAYS / M |
| Patient ID : | SEP302 | Date & Time : | 24-09-2025 09:58 AM |
| Refd By : | DR POOJA SUTAR | Modality : | X-ray |

X-RAY CHEST AP VIEW

FINDING :-

NG tube noted.

Diffused haziness noted at bilateral lung fields S/o Bronchopneumonia.

Both hila are normal.

Cardiophrenic and costophrenic angles are normal.

The trachea is central.

The mediastinal and cardiac silhouette are normal.

Cardiothoracic ratio is normal.

Bones of the thoracic cage are normal.

Soft tissues of the chest wall are normal.

IMPRESSION:

Diffused haziness noted at bilateral lung fields S/o Bronchopneumonia.

Clinical and lab correlation is recommended for confirmation.

Dr Kethipalli Nagaraju

MD

Consultant Radiologist

185215

Disclaimer: Disclaimer: This is an online interpretation of the images provided. If there is any clinical discrepancy, this investigation may be repeated or assessed by other tests. Patient's identification in online reporting is not established, so in no way this report can be utilized for any medicolegal purpose



Shop No. 5 & 6, Noori Blue Bells, Below Medford Hospital,
Nr. Bypass Y Junction, Kausa, Mumbra - 400 612



+91 97690 00093



Insight For A Healthier Tomorrow

MEDFORD

DIAGNOSTIC CENTRE

Powered by
MedBliss


Patient Name : BABA MOHD HAMZA SHAIKH
Age/Sex : 20 Days / Male
Ref Doctor : POOJA SUTAR
Client Name : MEDFORD HOSPITAL

Patient ID : 20250920-0363-3524
Sample Collected on : 24/09/2025, 08:36 AM
Registration On : 24/09/2025, 08:49 AM
Reported On : 24/09/2025, 09:07 AM

COMPLETE BLOOD COUNT (CBC)

| PARAMETER | VALUE | UNIT | RANGE |
|-------------------------------|---------------------------|---------------------------|---------------|
| Hemoglobin | 10.1 L | g/vdL | 12-16 |
| Red Blood Corpuscles | | | |
| PCV (HCT) | 30.9 L | % | 45-75 |
| RBC Count | 3.19 L | $\times 10^6/\mu\text{L}$ | 5.0-7.0 |
| RBC Indices | | | |
| MCV | 97.0 L | fL | 100.0-120.0 |
| MCH | 31.8 | pg | 31.0-37.0 |
| MCHC | 32.8 | g/dL | 31-36 |
| RDW-CV | 17.8 H | % | 11.5-14.5 |
| White Blood Corpuscles | | | |
| Total Leukocyte Count | 25060 H | /cumm | 4000-20000 |
| Differential Count | | | |
| Neutrophils | 35 | % | 21-41 |
| Lymphocytes | 58 | % | 20-71 |
| Eosinophils | 3 | % | 0-6 |
| Monocytes | 4 | % | 01-10 |
| Basophils | 0 | % | 0-1 |
| Platelets | | | |
| Platelet Count | 10000 L | /cumm | 150000-450000 |
| MPV | 7.6 | fL | 6.5-9.8 |
| RBC MORPHOLOGY | Hypochromia, Microcytosis | | |
| WBC MORPHOLOGY | Leucocytosis | | |
| PLATELETS ON SMEAR | Reduced on smear | | |

END OF REPORT


DR. PRIYANKA JAIN
(CONSULTING PATHOLOGIST)
REG. NO. 2017020327

Printed by lab

Shop No. 5 & 6, Noori Blue Bells, Below Medford Hospital,
Nr. Bypass Y Junction, Kausa, Mumbra - 400 612

+91 97690 00093



Patient Name : BABA MOHD HAMZA SHAIKH
Age/Sex : 20 Days / Male
Ref Doctor : POOJA SUTAR
Client Name : MEDFORD HOSPITAL

Patient ID : 20250920-0383-3524
Sample Collected on : 24/09/2025, 08:36 AM
Registration On : 24/09/2025, 08:49 AM
Reported On : 24/09/2025, 09:07 AM

ELECTROLYTE

| PARAMETER | VALUE | UNIT | RANGE |
|--------------|-------|-------|-----------|
| S. SODIUM | 136.0 | mEq/L | 135 - 155 |
| S. POTASSIUM | 4.27 | mEq/L | 3.5 - 5.5 |
| S. CHLORIDE | 105.9 | mEq/L | 95 - 109 |

END OF REPORT



DR. PRIYANKA JAIN
(CONSULTING PATHOLOGIST)
REG. NO. 2017020397

Printed by talib



Insight For A Healthier Tomorrow

MEDFORD

DIAGNOSTIC CENTRE

Powered by
MedBliss

Patient Name : BABA MOHD HAMZA SHAIKH Patient ID : 20250920-0363-3347
Age/Sex : 16 Days / Male Sample Collected on : 20/09/2025, 03:50 AM
Ref Doctor : POOJA SUTAR Registration On : 20/09/2025, 04:00 AM
Client Name : MEDFORD HOSPITAL Reported On : 20/09/2025, 04:18 AM

S CREATININE


| PARAMETER | VALUE | UNIT | RANGE |
|---------------|--------|-------|------------|
| S. CREATININE | 0.55 L | mg/dL | 0.7 to 1.4 |


ELECTROLYTE


| PARAMETER | VALUE | UNIT | RANGE |
|--------------|---------|-------|-----------|
| S. SODIUM | 123.6 L | mEq/L | 135 - 155 |
| S. POTASSIUM | 5.09 | mEq/L | 3.5 - 5.5 |
| S. CHLORIDE | 97.3 | mEq/L | 95 - 109 |

END OF REPORT

Printed by sadique


DR. PRIYANKA JAIN
(CONSULTING PATHOLOGIST)
REG.No. 2017020327

 Shop No. 5 & 6, Noori Blue Bells, Below Medford Hospital,
Nr. Bypass Y Junction, Kausa, Mumbra - 400 612

 +91 97690 00093



Nr. Bypass Y Junction, Kausa, Mumbra - 400 612



Insight For A Healthier Tomorrow

MEDFORD

DIAGNOSTIC CENTRE


Powered by
MedBliss

Patient Name : BABA MOHAMMED HAMZA SHAIKH Patient ID : 20250920-0365-3386
Age/Sex : 16 Days / Male Sample Collected on : 20/09/2025, 06:10 PM
Ref Doctor : POOJA SUTAR Registration On : 20/09/2025, 06:20 PM
Client Name : MEDFORD HOSPITAL Reported On : 20/09/2025, 07:48 PM

C REACTIVE PROTEIN (CRP) - QUANTITATIVE

| PARAMETER | VALUE | UNIT | RANGE |
|--------------------|----------|------|-------|
| CRP - QUANTITATIVE | 172.36 H | mg/L | 0 - 6 |




DR. PRIYANKA JAIN
(CONSULTING PATHOLOGIST)
REG.No. 2017020327

Printed by arsh



Shop No. 5 & 6, Noori Blue Bells, Below Medford Hospital,
Nr. Bypass Y Junction, Kausa, Mumbra - 400 612



+91 97690 00093